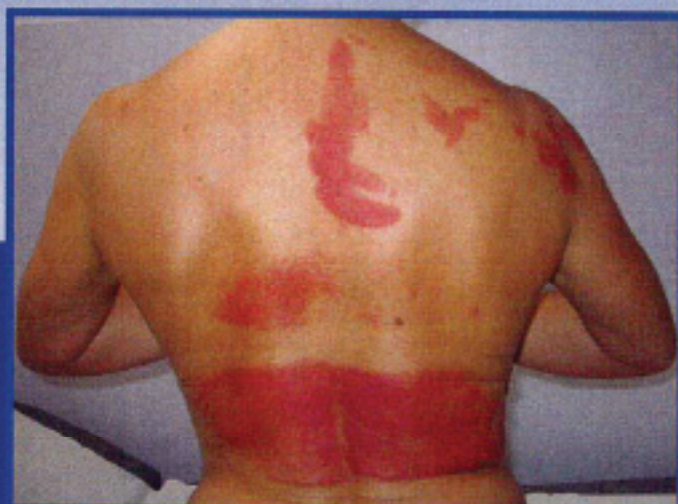

CONTACT DERMATITIS

CUTANEOUS ALLERGY

ENVIRONMENTAL AND OCCUPATIONAL DERMATITIS

THE OFFICIAL PUBLICATION OF THE EUROPEAN SOCIETY OF CONTACT DERMATITIS



EDITOR-IN-CHIEF: IAN R. WHITE

ASSISTANT EDITOR: Jonathan M.L. White

EDITOR EMERITUS: Torkil Menné

SECTION EDITORS

Kristiina Aalto-Korte *Occupational dermatology*

David Basketter *Toxicology*

Jeanne Duus Johansen *Clinical studies*

Jean-Pierre Lepoittevin *Molecular aspects and skin metabolism*

Carola Lidén *Risk assessment*

Stefan F. Martin *Immunology*

Wolfgang Uter *Epidemiology*

CONTACT DERMATITIS

63 No. 3 2010

CUTANEOUS ALLERGY
ENVIRONMENTAL AND OCCUPATIONAL DERMATITIS

Contents

Review Articles

Formaldehyde-releasers: relationship to formaldehyde contact allergy. Metalworking fluids and remainder. Part 1 117 *A. de Groot, J. Geier, M.-A. Flyvholm, G. Lensen & P.-J. Coenraads*

Formaldehyde-releasers: Relationship to formaldehyde contact allergy, Part 2: Metalworking fluids and remainder 129 *A. de Groot, J. Geier, M.-A. Flyvholm, G. Lensen & P.-J. Coenraads*

Original Articles

Patch testing and contact allergens in Ethiopia – results of 514 contact dermatitis patients using the European baseline series 140 *K. D. Bülcho, A. Ayele, D. Shibeshi & C. Lovell*

Patch test reactivity to feverfew-containing creams in feverfew-allergic patients 146 *E. Paulsen, L. P. Christensen, X. C. Fretté & K. E. Andersen*

Identification of metallic items that caused nickel dermatitis in Danish patients 151 *J. P. Thyssen, T. Menné & J. D. Johansen*

Sensitization to contact allergens and bronchial hyper-responsiveness 157 *E. Schrabel, Y. Schoefer, C.-M. Chen, T. Schäfer, H. Behrendt, J. Ring, H. -E. Wichmann & J. Heinrich*

Prevalence and cause of methylisothiazolinone contact allergy 164 *M. D. Lundov, J. P. Thyssen, C. Zachariae & J. D. Johansen*

Contact Points 168

Contact Points

C. S. Seitz & A. Trutmann: Differential diagnosis of mechanic's hands: think of Jo-1 syndrome. 168
S. Varma, D. Deblido, M.-A. Morren & A. Goossens: Sensitizing oat extracts in cosmetic creams: is there an alternative? 169
E. Neezyporenko & A. Blawieł: Allergic contact dermatitis to Elidel® cream itself? 171

R. Gallo, S. Paulino, G. Marcella & A. Porroli: Contact allergic contact dermatitis caused by ketoprofen in a tango dancer 172
M.-A. Morren, A. Van Loethem, S. Quarter & A. Goossens: How to test for contact allergy in patients with fragile skin 174

Cover Figure: Figure 2 from page 173, *Strikingly figured dermatitis on the patient's back.*

- piketoprofen. *Contact Dermatitis* 2008; 58: 113–115.
9. Pigatto P, Bigardi A, Legori A, Valsecchi R, Picardo M. Cross-reactions in patch testing and photopatch testing with ketoprofen, thiaprophenic acid, and cinnamic aldehyde. *Am J Contact Dermat* 1996; 7: 220–223.
 10. Fod C, Bonamonte D, Conserva A, Stingeni L, Lisi P, Lionetti N, Rigano L, Angelini G. Allergic and photoallergic contact dermatitis from ketoprofen: evaluation of cross-reactivities by a combination of photopatch testing and computerized conformational analysis. *Curr Pharm Des* 2008; 14: 2833–2839.
 11. Durbize E, Vigan M, Puzinat E et al. Spectrum of cross-photosensitization in 18 consecutive patients with contact photoallergy to ketoprofen: associated photoallergies to non-benzophenone-containing molecules. *Contact Dermatitis* 2003; 48: 144–149.

Address:

Dr Rosella Gallo
 Section of Dermatology – Di.S.E.M
 University of Genoa
 Viale Benedetto XV 7
 16132 Genoa
 Italy
 Tel: +390103538433
 Fax: +390103538401
 e-mail: rs.gallo@unige.it

How to test for contact allergy in patients with fragile skin

Contact Dermatitis 2010; 63: 174–175

Marie-Anne Morran, An Van Laethem, Sarah Quartier and An Goossens

Department of Dermatology, University Hospital Katholieke Universiteit Leuven, Leuven, Belgium

Key words: allergic contact dermatitis; bullous ichthyosiform erythroderma; dressing; epidermolysis bullosa; fragile skin; peeling skin syndrome; patch testing; silicone; technique.

Introduction

Contact allergy may complicate dermatological diseases that are associated with impaired skin barrier. In those with fragile skin (e.g. epidermolysis bullosa (1), bullous ichthyosiform erythroderma (2), or peeling skin syndrome (3)), patch testing may prove

challenging, as application of adhesive tape may induce erythema and loosening of the skin. This is not only bad for the patient, but it also makes interpretation of the tests difficult.

Case Report

A 36-year-old atopic man (history of eczema, hay fever, and asthma) was diagnosed with bullous ichthyosiform erythroderma (*KRT10* gene mutation (c.917T>C; p.Met306Thr). He suffered from acute dyshidrosis of his feet and hands, and distant lesions on his arms and upper trunk, suspected to be an allergic contact dermatitis. Patch testing had been performed twice in the past, demonstrating a strongly positive patch test reaction to potassium dichromate (++ at days 2 and 4), which had been considered to be relevant for his job as a construction worker. However, on one of these occasions, the patch tests had caused complete loosening of the skin where the adhesive tape had been applied. The patient had not always been able to avoid wearing leather shoes, particularly at work, and this was accompanied by extensive sweating; hence, shoe dermatitis was suspected.

Because of the previous problems during patch testing, the patient was reluctant to have new patch tests performed. Hence, before proceeding to patch testing, we applied different silicone dressings that might be used to secure patches, e.g. Reskin® (Bio-Racer, Tessenderlo, Belgium), Mepilex transfer®, Mepitel® and Mepitel lite® (Mölnlycke Health Care, Göteborg,

Sweden). Reskin has large holes, and is thinner and adhered better to the skin than the others. No adverse skin reactions were observed. We also tested the patient with a small piece of Micropore® (3M; Health Care®, Borken, Germany), which is usually applied as support for the patch test chambers in our department, but this did provoke redness.

Following this, patch tests were performed on the back of the patient with five allergens from the baseline series [mercapto-mix, colophonium, *p*-tertiary butylphenol formaldehyde resin, fragrance mix I, and budesonide] (TROLAB, Reinbek, Germany), as well as with phenol formaldehyde resin (PFR-2) (Chemotechnique Diagnostics, Vellinge, Sweden) and a topically used pharmaceutical preparation using Finn Chambers® (Epitest Ltd, Tuusula, Finland). Furthermore, 12 ethanolic extracts from 'hypo-allergenic' leathers (provided by several shoe manufacturers) were applied using van der Bend® chambers (van der Bend, Brielle, The Netherlands), together with pieces of the patient's own shoes placed directly on the Reskin dressing (Fig. 1). We advised the patient to sleep with a tightly-fitting T-shirt. Readings at day 2 and day 4 remained negative. There was no irritation, erythema or skin loosening. The patient later reported that two test sites had become erythematous at day 5.

Re-testing of the allergens, i.e. fragrance mix I and budesonide, corresponding to these test sites, confirmed, again at day 5, a positive reaction (+: erythema and infiltration) only




Fig. 1. Substances diluted in ethanol on van der Bend chambers and those diluted in pet. on Finn Chambers®, as well as shoe pieces placed directly onto Reskin® silicone dressing.

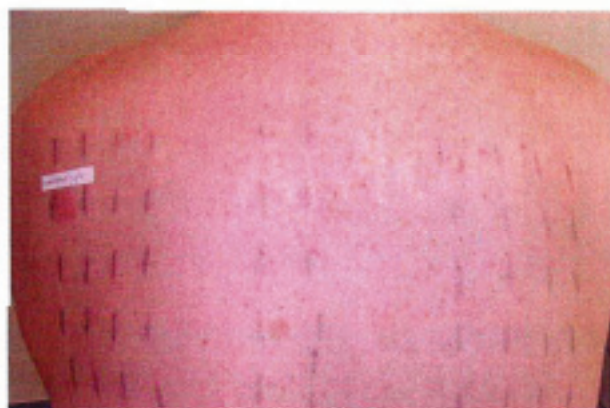

Fig. 2. Patch testing on fragile skin using Reskin® silicone dressing; no irritation, erythema or skin loosening were observed; there was a clear positive reaction to amcinonide (++) day 7).

to budesonide (0.01% pet.), a marker for corticosteroid allergy (Fig. 2). Six weeks later, the patient was additionally tested with a corticosteroid series (4), in order to investigate possible cross-reactions, again using Reskin to fix the chambers and with the patient wearing a tightly-fitting T-shirt. No technical problems were encountered, and the patient showed a (late) positive reaction to amcinonide only (++) at day 7) (Fig. 2). This is another acetamide that cross-reacts with budesonide. The relevance to the patient's dermatitis could not be established.

Discussion and Conclusion

Contact allergy in patients with fragile skin seems to be rare, but cases might be under-reported or remain undiagnosed. We observed allergic contact dermatitis resulting from shoes in a young patient with epidermolysis simplex (data on file). In the literature, doxepin, used to temper the itch of

epidermolysis bullosa lesions, has been reported twice as a contact allergen (5, 6).

Patch testing in such cases is possible without major problems if silicone dressings are used. Indeed, Horn et al. (6) advised testing on the patient's arm, putting the chambers without Scanpor® (Laboratoires Lohmann & Rauscher s.a., Liège, Belgium) directly on Mepitel (Mölnicke, Health Care, Göteborg, Sweden), and covering the test sites with Tubifast® (Mölnlycke Health Care, Göteborg, Sweden) and an elastic stockinette.

We applied the allergens to the patient's back with chambers directly fixed on Reskin, which remained well in place even without the use of an elastic stockinette, but with the patient wearing a tight T-shirt instead. This recently commercialized dressing has holes (Fig. 1), and hence is not occlusive, and might therefore be better tolerated than other dressings. Indeed, in some blistering diseases,

sweating is known to favour skin loosening, especially in those with keratin mutations. Moreover, it afforded better contact with the skin than the other materials we tested.

Conflicts of interest: The authors have declared no conflicts.

References

1. Fine J D, Eady R A J, Bauer E A et al. The classification of inherited epidermolysis bullosa (EB): report of the third international consensus meeting on diagnosis and classification of EB. *J Am Acad Dermatol* 2008; 58: 931–950.
2. Lacz N L, Schwartz R A, Kibiczak G. Epidermolytic hyperkeratosis: a keratin 1 or 10 mutational event. *Int J Dermatol* 2005; 44:1–6.
3. Ilkay T, Demirtaşoğlu M, Akarsu S et al. Peeling skin syndrome. *Env J Dermatol* 2006; 16: 287–289.
4. Baeck M, Chemelle J A, Terreux R, Drieghe J, Goossens A. Delayed hypersensitivity to corticosteroids in a series of 315 patients: clinical data and patch test results. *Contact Dermatitis* 2009; 61: 163–175.
5. Wakelin S H, Rycroft R J G. Allergic contact dermatitis from doxepin. *Contact Dermatitis* 1999; 40: 214.
6. Horn H M, Tidman M J, Aldridge R D. Allergic contact dermatitis due to doxepin cream in a patient with dystrophic epidermolysis bullosa. *Contact Dermatitis* 2001; 45: 115.

Address:

An Goossens

Department of Dermatology,
University Hospital St. Rafaël,
Katholieke Universiteit Leuven,
Kapucijnenvoer 33,
B-3000 Leuven, Belgium.

Tel: + 32 16 33 78 60

Fax: + 32 16 33 70 12

e-mail: an.goossens@uz.kuleuven.ac.be